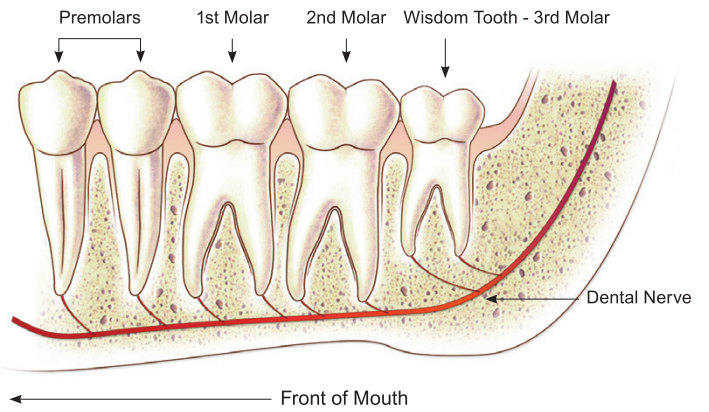


The Story of Impacted Wisdom Teeth

Investigation of Wisdom Teeth between ages 15 to 18 with a full mouth X-Ray (OPG) is advisable to detect the presence and position of the Wisdom Teeth.

Early assessment allows Wisdom Teeth to be removed before they cause trouble and prior to full root development. At this stage the bone is still soft, making the wisdom teeth easier to remove and post-op recovery quicker.

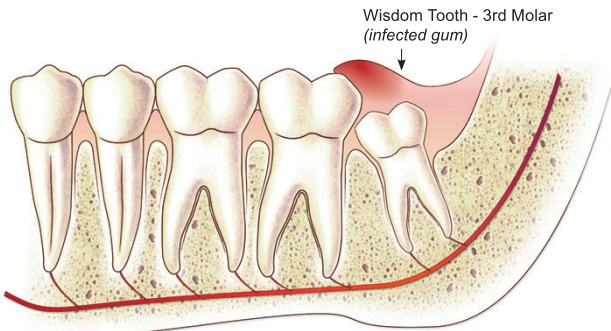
NORMAL ERUPTED POSITION (uncommon) LOWER JAW



For a small percentage of people they erupt normally behind the 2nd molar and can be a useful tooth.

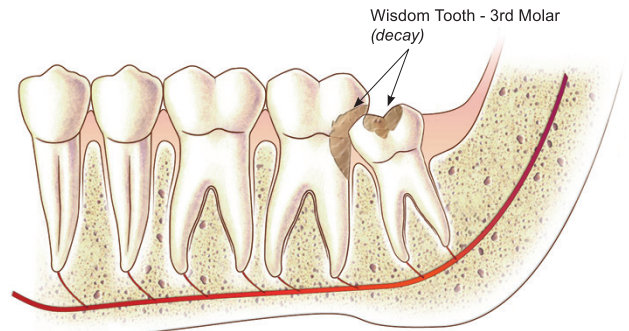
Impacted Wisdom Teeth can cause:

1 INFECTED GUM (common)



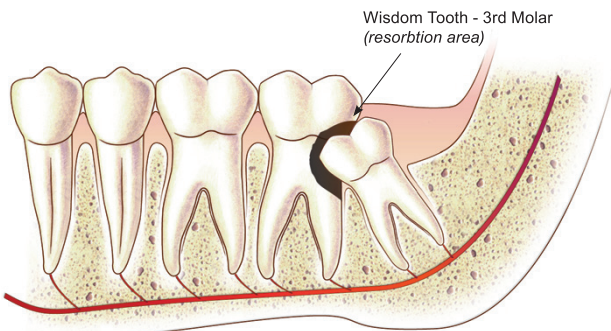
Infection or ulceration of overlying or surrounding gum.

2 DECAYED AREA (occasional)



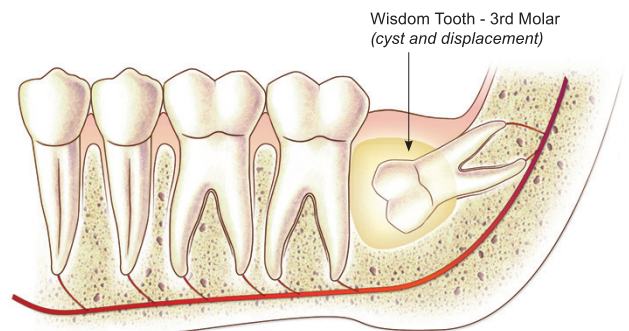
Decay of the wisdom tooth itself and/or of the next tooth.

3 RESORPTION CAVITY (rare)



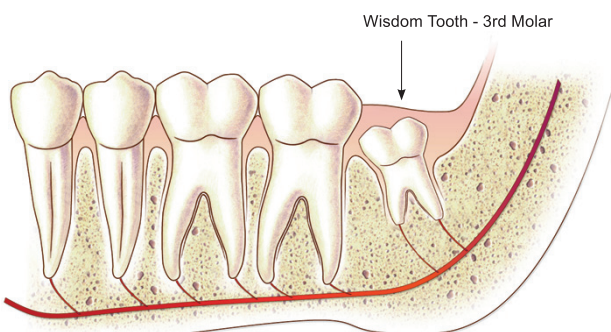
Resorption of the next tooth.

4 CYST AND DISPLACEMENT (occasional)



Destruction of the surrounding bone by the formation of a cyst.

5 IDEAL REMOVAL (age 16-18 years)



Wisdom teeth develop in teenage years. Root development is usually completed around age 20. Removal in 16-20 year age group is easiest.

6 HEALED SITE (after removal)

